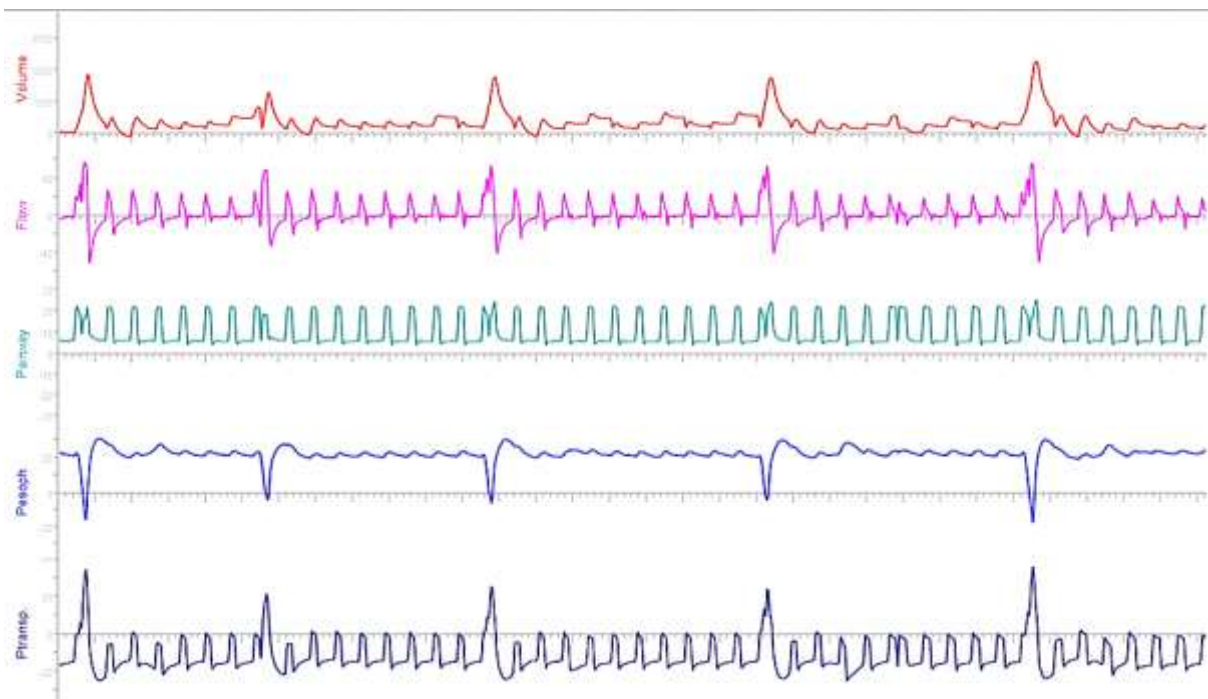


Supplementary Material

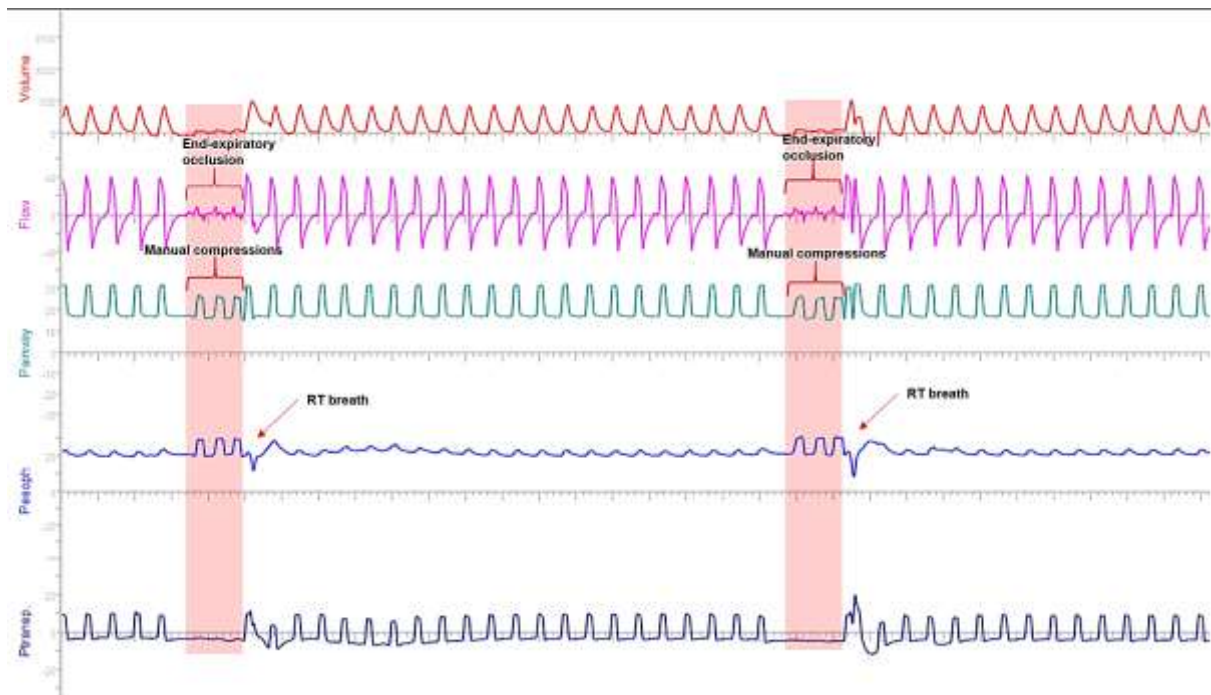
Figure S1. Reverse breaths of different natures of origin

- A. Entrained reverse triggered breath in a deeply sedated critically ill patient under protective mechanical ventilation and negative end expiratory transpulmonary pressure (PC-IMVs)



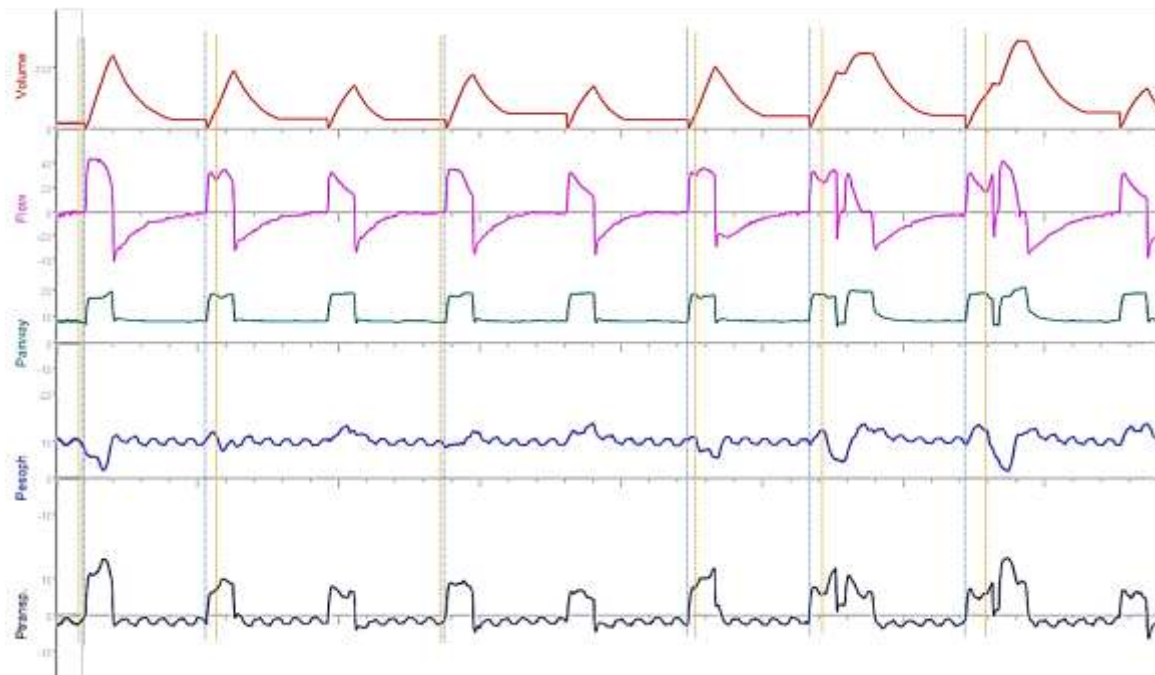
In this case the high impedance of the system in a hyper obese patient, the low PEEP used, and the preset mode used converge in the generation of low exhaled tidal volumes, facilitating the occurrence of the phenomenon.

B. Reverse triggered breath after manual compressions during end-expiratory occlusion for esophageal balloon validation (PC-IMVs)



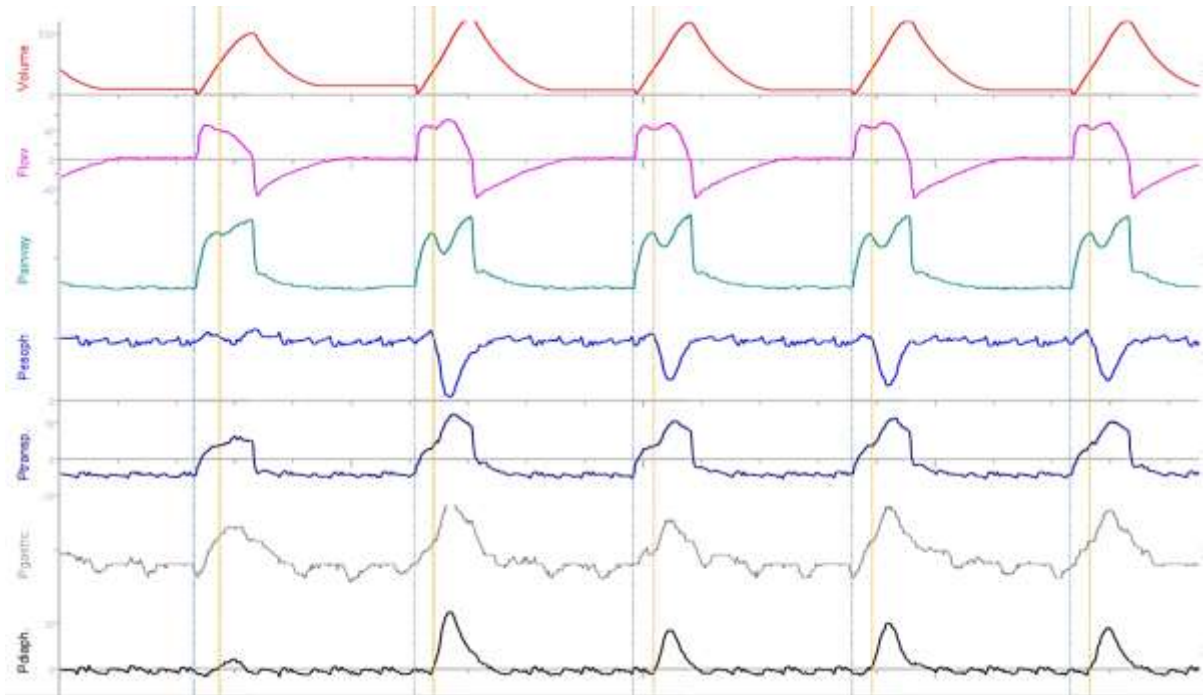
Thoracic compressions applied to this deeply sedated patient elicit a motor response to the external stimulus. The presence of diaphragmatic contractions can be observed. The light red stripes show the period of occlusion.

C. Reverse triggered breath without entrainment in a critically ill patient under invasive mechanical ventilation (PC-IMVs)



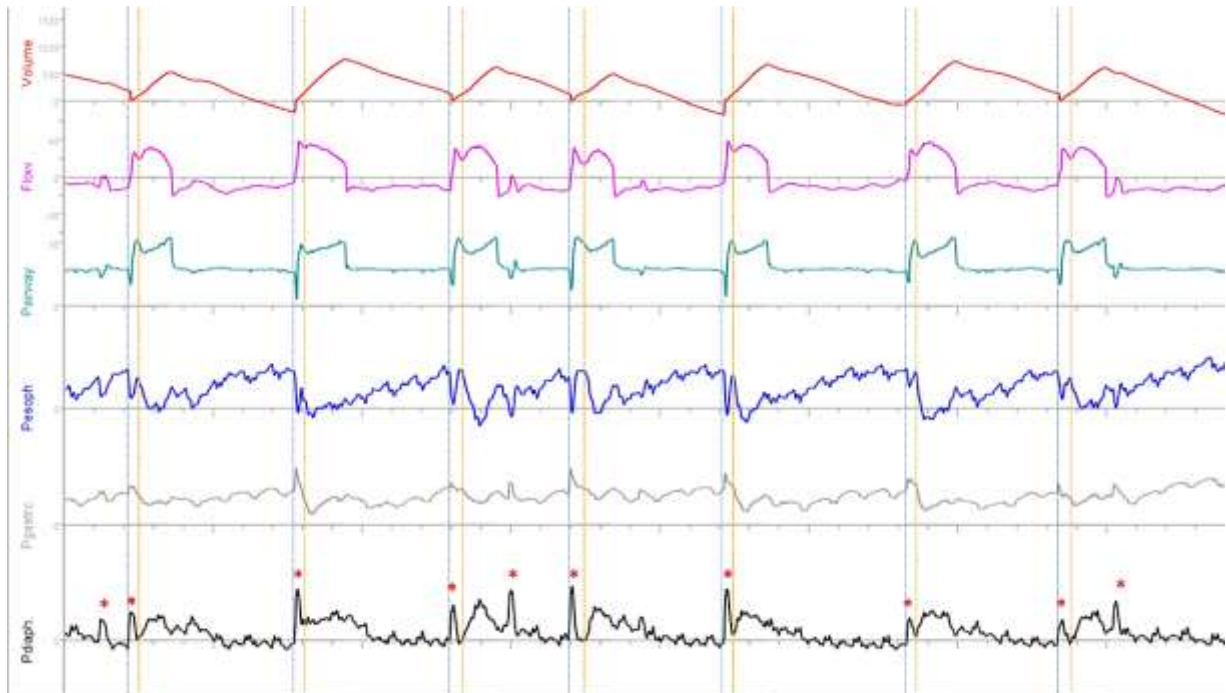
Presence of reverse respirations in a patient with RASS -4, under opioid doses, during transition to spontaneous ventilation. The erratic relationship between insufflation and onset of effort can be observed, suggesting non-entrained respirations, probably due to the use of opioids and a higher than neural set rate. Some of them produce double triggering with breath stacking. The dotted blue lines show the beginning of the stimulus (ventilator insufflation), while the dashed orange lines show the beginning of inspiratory effort.

D. Reverse triggered breath with entrainment (1:1) in a critically ill patient under invasive mechanical ventilation (PC-IMVs) with esophageal and gastric pressure monitoring



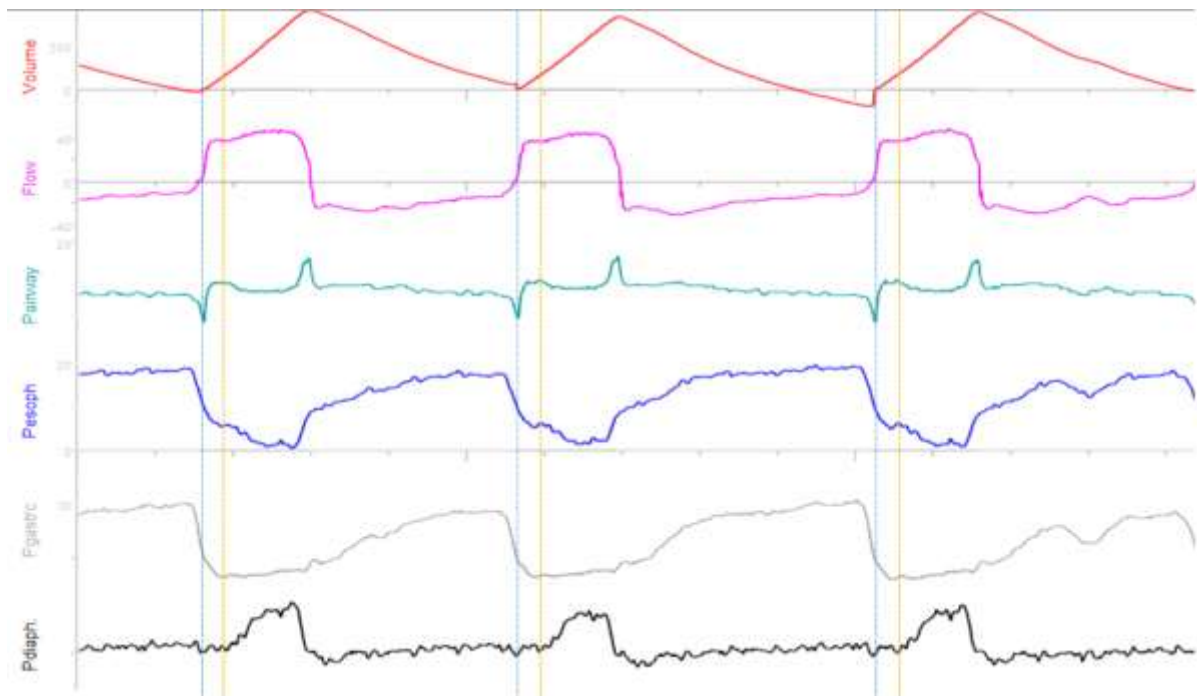
The dotted blue lines show the beginning of the stimulus (ventilator insufflation), while the dashed orange lines show the beginning of inspiratory effort.

E. Diaphragmatic myoclonus triggers the ventilator and is associated with premature triggering in a critically ill patient under pressure support (PC-CSVs) with esophageal and gastric pressure monitoring



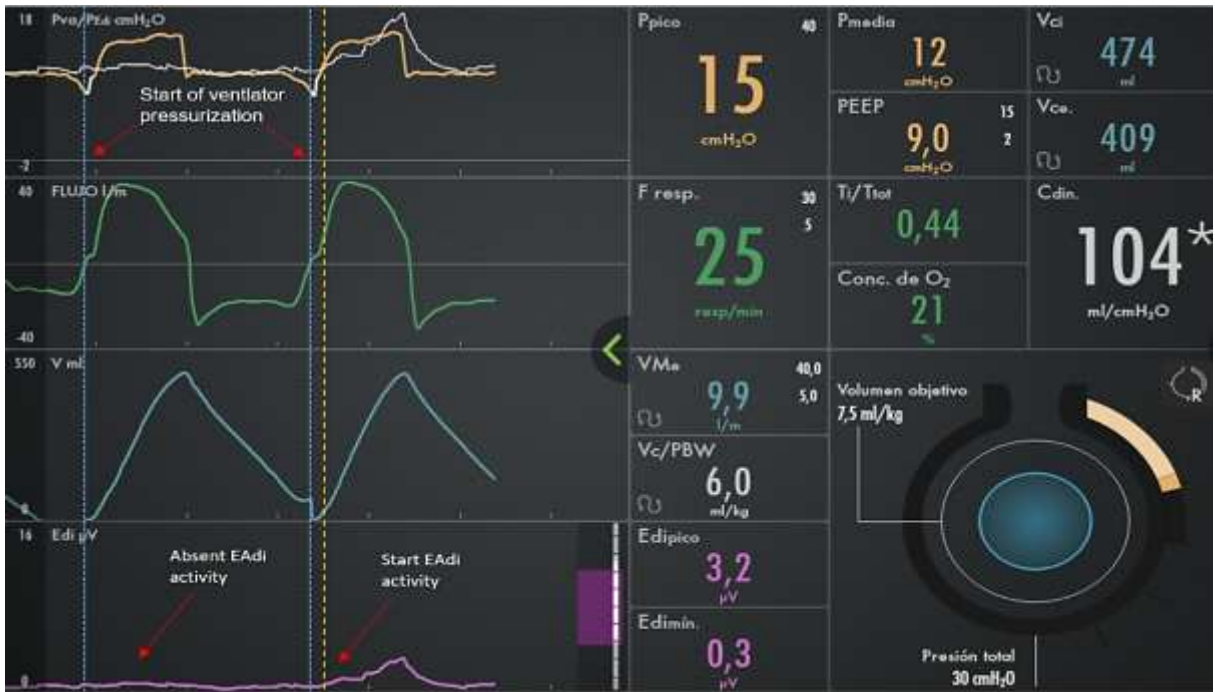The dotted blue lines show the beginning of the stimulus (ventilator insufflation), while the dashed orange lines show the beginning of inspiratory effort. The red asterisk shows myoclonus.

F. Expiratory Muscle Relaxation Induce Trigger in a critically ill patient under invasive mechanical ventilation (PC-CSVs) and the appearance of reverse triggered breaths.



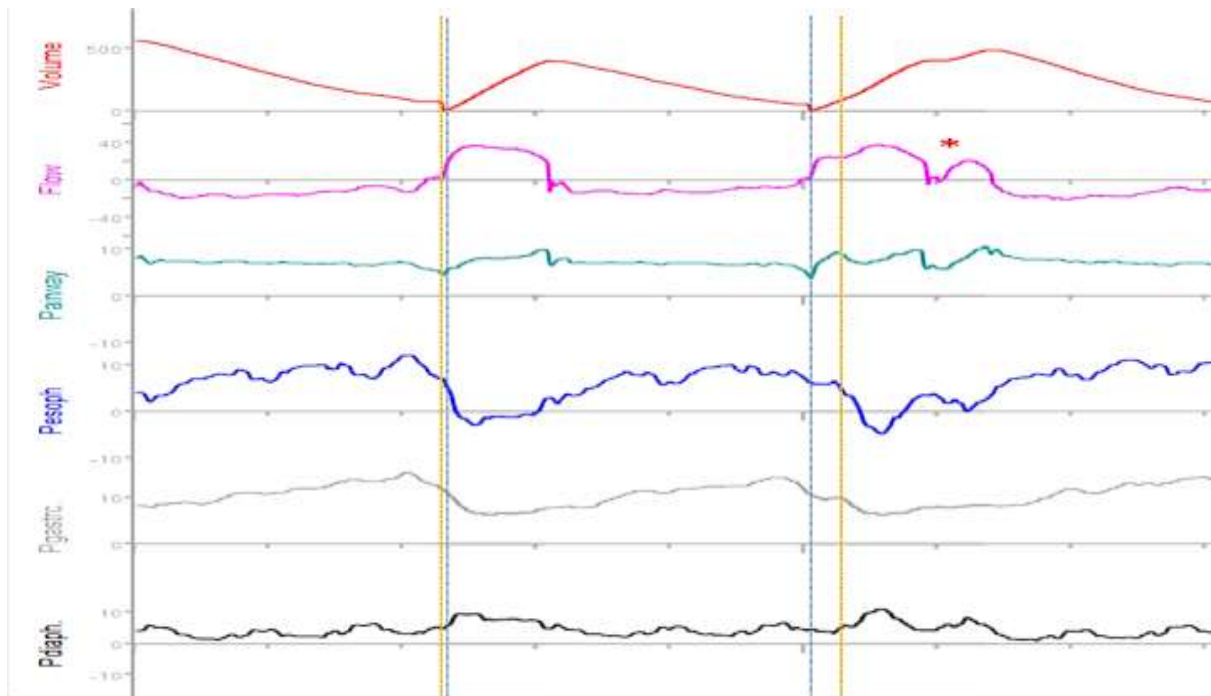
The strong presence of expiratory activity favors the firing performed not by the inspiratory muscles, but by the relaxation of the expiratory muscles. The inflexion in the flow can be observed when the patient's inspiratory effort appears during the mechanical inspiratory time. The dotted blue lines show the beginning of the stimulus (ventilator insufflation), while the dashed orange lines show the beginning of inspiratory effort.

G. Expiratory Muscle Relaxation Induce Trigger in a critically ill patient under invasive mechanical ventilation (PC-CSVs) and EAdi monitoring



The dotted blue lines show the beginning of the stimulus (ventilator insufflation), while the dashed orange lines show the beginning of inspiratory effort assed with Electrical Activity of the Diaphragm (EAdi).

H. Expiratory Muscle Relaxation Induce Trigger in a critically ill patient under invasive mechanical ventilation (PC-CSVs) and esophageal and gastric pressure monitoring



The presence of ERIT and the neural timing of inspiration cause a double trigger. The dotted blue lines show the beginning of the stimulus (ventilator insufflation), while the dashed orange lines show the beginning of inspiratory effort.