



Candida pneumonia: Innocent colonizer or silent killer? A case report

Sergio G Monasterios-López, ¹ Martín A Ríos-Ayala, ² Carmen . Hernández-Cárdenas, ³ Gustavo Lugo-Goytia, ⁴ Jaritz G Lagunez Caramón ⁵

DOI: <https://doi.org/10.53097/JMV10128>

Cite: Monasterios-López SG, Ríos-Ayala MA, Hernández-Cárdenas CM, Lugo-Goytia G, Lagunez Caramón JG. Candida Pneumonia: Innocent Colonizer or Silent Killer? A Case Report. J Mech Vent 2025; 6(2):97-100.

Abstract

Candida in tracheal aspirate is often classified as simple colonization or potentially fatal pulmonary infection. Fungal respiratory infections are of particular concern in the growing population of immunocompromised patients. Candida pneumonia is a rare and potentially fatal condition, with mortality rates reaching up to 70%. Demonstration of Candida species through lung biopsy along with evidence of inflammation is the only way to confirm this entity.

Keywords: Candida, Colonization, Pneumonia, Antifungal treatment, Acute respiratory failure.

Authors

1. MD, Critical Care and Intensive Specialist, Fellowship in Respiratory Intensive Care (UCIR) (INER).
2. MD, Critical Care and Intensive Specialist, Fellowship in Respiratory Intensive Care, Assistant Professor and Staff Member at the Respiratory Intensive Care Unit (UCIR) (INER).
3. General Director of the National Institute of Respiratory Diseases Ismael Cosío Villegas (INER).
4. MD, PhD, Critical Care and Intensive Specialist, Anesthesiologist, Staff Member at the Respiratory Intensive Care Unit (UCIR) (INER).
5. MD, Critical Care and Intensive Specialist, Fellowship in Respiratory Intensive Care (UCIR) (INER).

Corresponding author: sergiogustavomonasterioslopez@gmail.com

Conflict of interest/Disclosures: None

Introduction

Pulmonary infections caused by *Candida* are rare but can be life-threatening, posing a significant diagnostic challenge. Differentiating colonization from invasive infection is crucial, as *Candida* pneumonia requires prompt recognition and urgent antifungal treatment.¹ We present a confirmed case of *Candida* pneumonia, highlighting the predisposing factors, clinical, microbiological, and imaging findings, as well as the therapeutic approach and clinical outcome. Given the rarity of this condition, this report aims to emphasize its clinical impact as a potentially fatal disease that necessitates timely intervention.^{2,3}

Case Report

A 46-year-old man with a history of bronchial asthma, on chronic inhaled steroid therapy, was admitted to the emergency department due to dyspnea, wheezing, and signs of respiratory distress that did not subside after administration of inhaler-based beta-agonist medication.

Advanced airway management was initiated, followed by mechanical ventilation and transfer to the intensive care unit. During hospitalization, the patient received broad-spectrum antibiotic therapy without improvement. Imaging studies were performed.

The chest CT findings suggested probable bronchopulmonary aspergillosis due to the presence of micronodules. A bronchoscopy was performed, and a sample of respiratory tissue was sent for pathology examination.

Histopathological Diagnosis

Histochemical stains with periodic acid-Schiff (PAS) and Grocott highlight the yeast walls and pseudohyphae. (Magnification 100x).

Diagnosis was made by biopsy, leading to the initiation of antifungal treatment for *Candida albicans* was started. Clinical symptoms improved, and ventilatory parameters normalized until weaning was achieved.

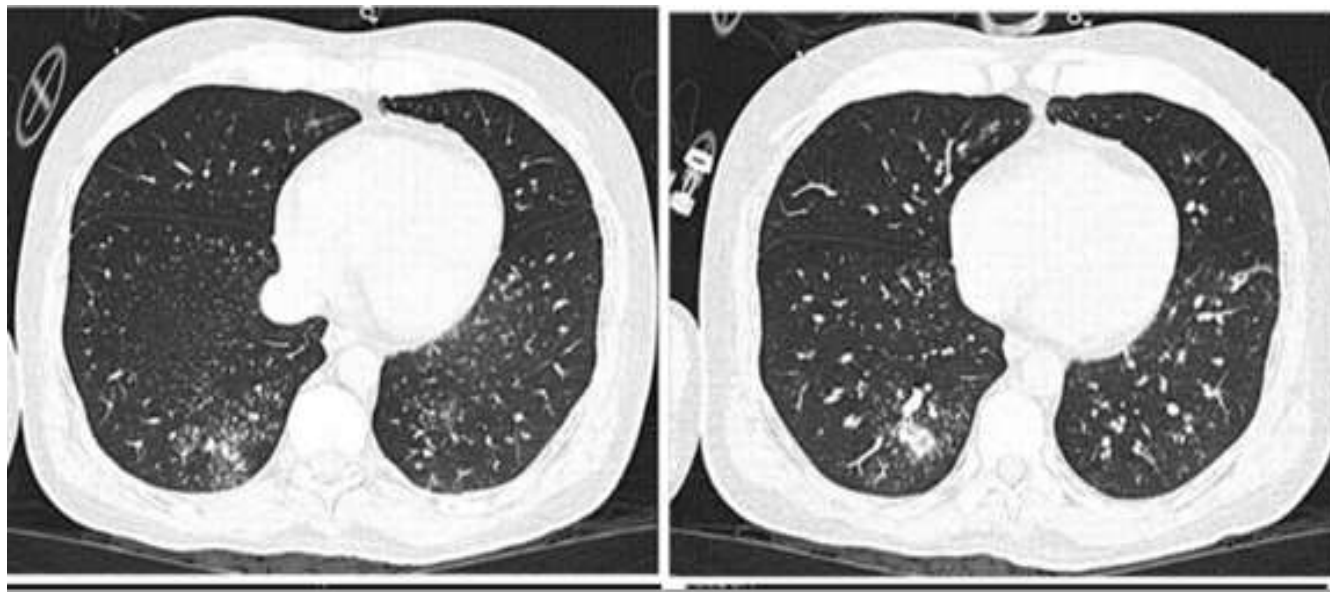

Figure 1: Chest CT scan showing a diffuse micronodular pattern with peripheral distribution in the lower lobes, predominantly on the right side, coexisting with a tree-in-bud pattern.

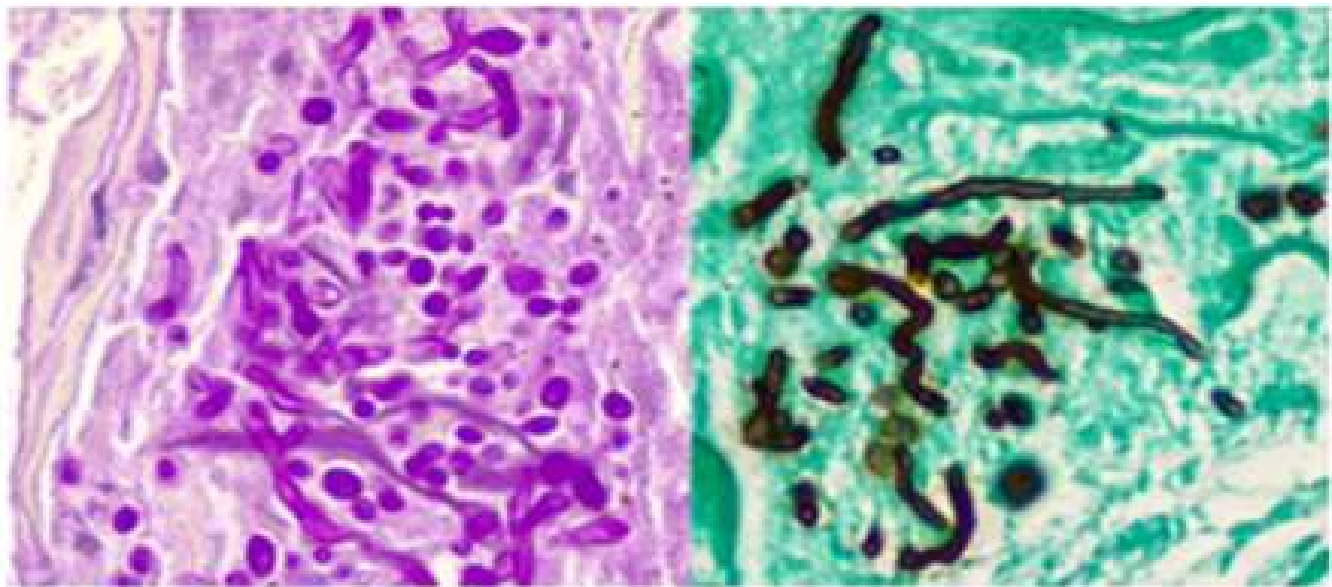


Figure 2: Histological section showing yeast cells measuring 3 to 5 μm in diameter and pseudohyphae morphologically corresponding to *Candida* spp., located in the keratinocytes and adjacent stroma. (Magnification 100x; hematoxylin and eosin).

Discussion

Candida pneumonia, identified by genus, is a rare infection frequently associated with poor prognosis.⁴ *Candida* species are commonly found in tracheal aspirate samples, even in healthy individuals. After 48 hours of intubation and ventilation, up to 20% of patients are colonized, and this proportion increases with the duration of ventilation, while *Candida* pneumonia is not geographically endemic like other fungal lung infections, its occurrence is strongly linked to hospital environments and patient-specific risk factors.⁵

Findings on chest CT are relatively nonspecific, leading to consideration of other causes of different etiologies (5). There is insufficient evidence to support the initiation of treatment in suspected pneumonia with *Candida* in endotracheal secretions.⁶

Symptomatology and biopsy were fundamental for proper interpretation and early diagnosis, resulting in an adequate response to treatment. These organisms often cause more indolent infections in immunocompetent individuals. Symptoms of *Candida* Pneumonia are similar to bacterial pneumonia but often in immunocompromised patients, in this case patient had fever, chills, dyspnea, nonproductive cough, patchy infiltrates on imaging, but culture confirmation is needed. Typically occurs in intubated ICU patients or those with severe immunosuppression.⁷

It is important to consider the diagnosis of *Candida* pneumonia in patients with acute progression with systemic manifestations, radiological, and laboratory evidence, as early treatment can impact morbidity and mortality.⁸⁻¹⁰

Biomarkers play a crucial role in the early detection and diagnosis of *Candida* infections, helping to differentiate colonization from invasive disease. According to recent studies, the use of serum (1 \rightarrow 3)- β -D-glucan (BDG) and mannan/anti-mannan antibodies has demonstrated significant diagnostic value in identifying invasive *Candida* infections. These biomarkers can facilitate the early initiation of antifungal treatment, potentially improving patient outcomes, especially in critically ill patients, where delayed treatment increases the risk of mortality.^{11,12}

Conclusion

Candida pneumonia should be considered in critically ill immunocompetent patients. Immediate treatment should be initiated to improve survival.

Reference

1. Lamoth F, Alexander BD. Nonmolecular methods for the diagnosis of respiratory fungal infections. *Clin Lab Med* 2014; 34(2):315-336.
2. Dermawan JKT, Ghosh S, Keating MK, et al. *Candida* pneumonia with severe clinical course, recovery with

antifungal therapy and unusual pathologic findings: A case report. *Medicine (Baltimore)* 2018; 97(2):e9650.

3. Lindau S, Nadermann M, Ackermann H, et al. Antifungal therapy in patients with pulmonary *Candida* spp. colonization may have no beneficial effects. *J Intensive Care* 2015; 3(1):31.

4. Tan M, Wang J, Hu P, et al. Severe pneumonia due to infection with *Candida krusei* in a case of suspected Middle East respiratory syndrome: A case report and literature review. *Exp Ther Med* 2016; 12(6):4085-4088.

5. Schnabel RM, Linssen CF, Guion N, et al. *Candida* pneumonia in intensive care unit? *Open Forum Infect Dis* 2014; 1(1):ofu026.

6. Albert M, Williamson D, Muscedere J, et al. *Candida* in the respiratory tract secretions of critically ill patients and the impact of antifungal treatment: a randomized placebo-controlled pilot trial (CANTREAT study). *Intensive Care Med* 2014; 40(9):1313-1322.

7. Meena DS, Kumar D. *Candida* Pneumonia: An innocent bystander or a silent killer? *Med Princ Pract* 2022;

31(1):98-102.

8. McCarty TP, White CM, Pappas PG. Candidemia and invasive candidiasis. *Infect Dis Clin North Am* 2021; 35(2):389-413.

9. Sobel JD, Vazquez J. Candidemia and systemic candidiasis. *Semin Respir Infect* 1990; 5(2):123-137.

10. Di Mango AL, Zanetti G, Penha D, et al. Endemic pulmonary fungal diseases in immunocompetent patients: an emphasis on thoracic imaging. *Expert Rev Respir Med* 2019; 13(3):263-277.


11. Su KC, Chou KT, Hsiao YH, et al. Measuring (1,3)- β -D-glucan in tracheal aspirate, bronchoalveolar lavage fluid, and serum for detection of suspected *Candida* pneumonia in immunocompromised and critically ill patients: a prospective observational study. *BMC Infect Dis* 2017; 17(1):252.

12. F Lamoth, H Akan, D Andes, M Cruciani, O Marchetti, L Ostrosky-Zeichner, Z, Racil, C J Clancy, Assessment of the Role of 1,3- β -d-Glucan Testing for the Diagnosis of Invasive Fungal Infections in Adults. *Clin Infect Dis* 2021; 72(Suppl 2):S102-S108.



2025

SOCIETY OF MECHANICAL VENTILATION CONFERENCE



EXPAND YOUR KNOWLEDGE, NETWORK, IMPROVE OUTCOME, HAVE FUN



Speakers

JOHN DOWNS MD
ANDREW FENG MD
BRENT MATSUDA MD
CHERIE CHU PHARM D
DAVID WILLMS MD
KIMIYO YAMASAKI RRT

BENJAMIN DAXON MD
RYOTA SATO MD
SAMUEL EVANS MD
STEPHEN TUNNEL RRT
EHAB DAOUD MD

DATE: JUNE 30 - JULY 1, 2025
7:00 AM TO 12: 30PM

LOCATION: KUAKINI MEDICAL CENTER AUDITORIUM
347 NORTH KUAKINI STREET, HONOLULU

////// IN PERSON OR ONLINE
REGISTER TODAY

<https://societymechanicalventilation.org/2025-2/>